



## Case Report

# A rare case of deformity: Fibrodysplasia ossificans progressiva

Vykuntaraju K. Gowda<sup>1</sup>, Sandeep Rangaiah<sup>1</sup>, Varunvenkat M. Srinivasan<sup>1</sup>, Dhananjaya Kotebagilu Narayana Vamymanmane<sup>2</sup>

Departments of <sup>1</sup>Pediatric Neurology and <sup>2</sup>Pediatric Radiology, Indira Gandhi Institute of Child Health, Bengaluru, Karnataka, India.

### \*Corresponding author:

Vykuntaraju K. Gowda,  
Department of Pediatric  
Neurology, Indira Gandhi  
Institute of Child Health,  
Bengaluru, Karnataka, India.

drknvraju08@gmail.com

Received: 24 October 2022  
Accepted: 09 February 2023  
Epub Ahead of Print: 23 February 2023  
Published: 08 March 2023

### DOI

10.25259/KPJ\_26\_2022

### Quick Response Code:



## ABSTRACT

Fibrodysplasia ossificans progressiva (FOP) is a rare genetic disorder and the most debilitating condition of heterotopic ossification in humans. Misdiagnosis is common and they suffer from complications of incorrect diagnosis and subsequent inappropriate treatment hence, to create awareness, we are reporting a genetically confirmed case of FOP. A 10-year-old boy, born to a non-consanguineously married couple, presented with progressive stiffness of the neck, back, and limbs with restriction of movements. Examination showed two firm non-tender immobile swellings over the back with scoliosis towards the left side. A bilateral hallux valgus deformity with restricted movements of the great toe was noted. Outside treated as mixed connective tissue disorder without any improvement. The X-ray showed calcifications in the swellings. Genetic testing showed the pathogenic variant in the activin A receptor type 1 gene. The FOP should be considered in children presenting with progressive stiffness, deformity of the feet, and ectopic ossifications to avoid misdiagnosis and inappropriate treatment.

**Keywords:** Activin A receptor type 1 gene, Bilateral hallux valgus, Fibrodysplasia ossificans progressiva

## INTRODUCTION

Fibrodysplasia ossificans progressiva (FOP) is an autosomal dominantly inherited disorder of connective tissues characterised by progressive heterotopic (extra-skeletal) calcification. In the eighteenth century, it was called by the name myositis ossificans progressiva by von Dusch in 1868. Since the muscles were only secondarily affected, the term fibrodysplasia was coined by Bauer and Bode in 1940. It is caused by fibroproliferative lesions in tendons, ligaments, and skeletal muscles.<sup>[1]</sup> Activating mutations in the activin A receptor type 1 (ACVR1) gene are responsible for causing this disease.<sup>[2]</sup> FOP is a very rare disorder with a prevalence of approximately one case in 2 million individuals worldwide.<sup>[3]</sup> Most of the FOP cases are misdiagnosed as having osteosarcoma, pseudohypoparathyroidism, or hypervitaminosis D before heterotopic ossifications.<sup>[4]</sup> Hence, we are reporting this case.

## CASE REPORT

A 10-year-old male child, born to a non-consanguineously married couple with a normal perinatal history, presented with progressive stiffness of the neck, limbs, and back with restriction of movements noticed for the 5<sup>th</sup> month of life. At 5 months of age, the mother noticed swelling in the back of the neck which was initially soft but subsequently become hard. The later child

This is an open-access article distributed under the terms of the Creative Commons Attribution-Non Commercial-Share Alike 4.0 License, which allows others to remix, transform, and build upon the work non-commercially, as long as the author is credited and the new creations are licensed under the identical terms.

©2022 Published by Scientific Scholar on behalf of Karnataka Paediatric Journal

gradually developed similar swellings over the nape of the neck, back, shoulder and lower limbs. The swellings were painless and immobile. It was associated with bending of the spine towards the right side, which became prominent at 3 years of age. The child also started developing stiffness and restricted movements of the left upper limb predominantly at the elbow joint. Initially, finger movements were normal, later, the fine movements of both hands were involved. Starting from 8 years of age, the child developed difficulty in opening the mouth and later progressed to difficulty in talking. Child development was normal in all the domains, but his motor activities were limited due to stiffness.

On examination, the weight of 14 kg (<3<sup>rd</sup> centile) and height of 137 cm (25<sup>th</sup>–50<sup>th</sup> centile), epicanthal folds, low set ears, restricted mouth opening (Mallampati grade III), short neck, barrel-shaped chest with widely spaced nipples, scoliosis and two firm non-tender immobile swellings over the back with scoliosis towards the left side [Figures 1a and b] and left gunstock deformity with greatly reduced range of movements. Bilateral hallux valgus present [Figure 1c] with restricted movements of the great toe was noted. Systemic examination was normal. Routine investigations such as complete blood counts, erythrocyte sedimentation rate, C-reactive protein, anti-streptolysin O, and anti-nuclear antibodies were normal. The serum creatine kinase levels were normal. The X-ray showed scoliosis with convexity towards the left, partial fusion of upper lumbar vertebral bodies on the right side with extensive ossifications in adjacent soft tissues, ossification of the interspinous ligament with a fusion of the cervical spinous processes, osteopenia in tarsal, metatarsal and phalanges and hallux valgus deformity in the left leg [Figure 2]. Based on the above clinical and radiological features, we suspected FOP. Targeted next-generation sequencing showed pathogenic variant c.617

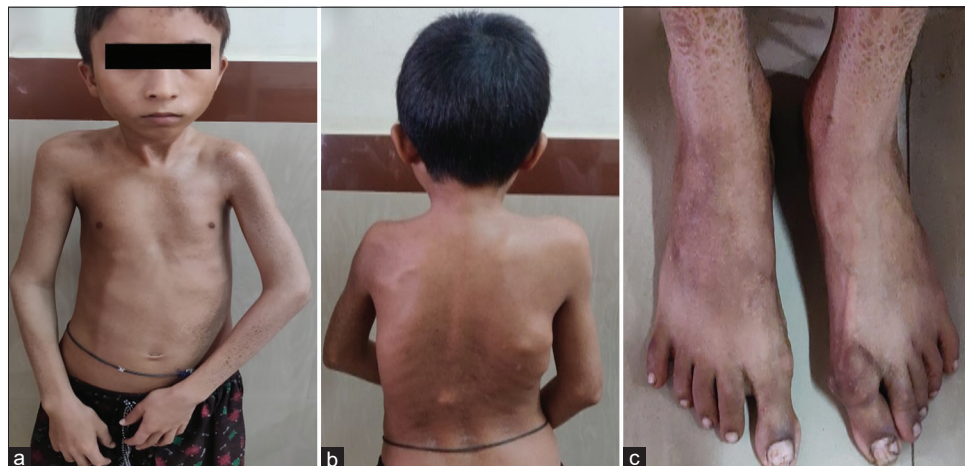G>A; P.R206H allele mutation in exon 6 of the ACVR1 gene, hence confirming our diagnosis of FOP.

## DISCUSSION

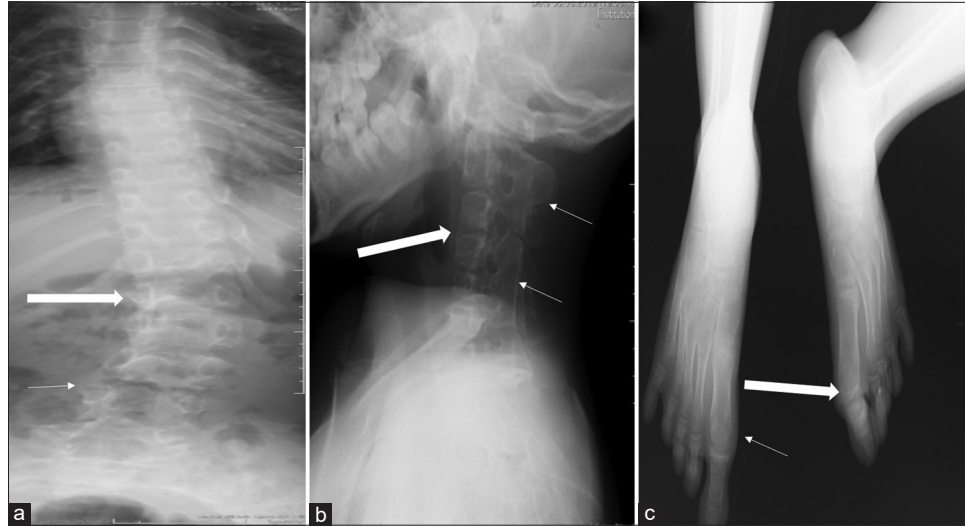
FOP is a rare debilitating connective tissue disorder characterised by a deformity of the great toes from infancy and postnatal heterotopic ossification.<sup>[5]</sup> Congenital malformation of the great toes (98%) is the characteristic diagnostic feature of the disease, which is usually associated with episodes of soft-tissue swelling (flare-ups) which can spontaneously regress or turn into heterotopic bone. Formations of this heterotopic bone over joints lead to ankylosis and progressive immobility.<sup>[6]</sup>

Here, we describe an Indian boy with multiple painless, swellings over the body with restriction of movements at various joints. We diagnosed him as FOP based on the stiffness of limbs, deformity of the feet and ectopic ossifications and confirmed by the pathogenic variant in the ACVR1 gene on next-generation sequencing. It has been reported that a biopsy of the lesion in these patients results in clinical deterioration and should be avoided.<sup>[6]</sup> Hence, we did not do the biopsy, and also, the biopsy will not differentiate FOP from other causes of heterotopic ossifications.

The pathogenesis of FOP is dysregulated bone morphogenetic protein (BMP) signaling. Classic FOP is caused by a single common heterozygous mutation (617G>A; R206H) identified in the cytoplasmic domain of ACVR1/activin-like kinase 2, a BMP type I receptor, in five small multigenerational families and all sporadically affected individuals.<sup>[2]</sup> Evidence suggests that the involvement of the inflammatory component of the immune system plays a critical role in FOP.<sup>[7]</sup> The presence of macrophages, lymphocytes, and mast cells in the early FOP lesions, macrophage and lymphocyte-associated death



**Figure 1:** (a) Clinical photograph of the child showing flexion at bilateral elbow joints. (b) Scoliosis of the dorsolumbar spine with swelling over the midline and left scapula. (c) Hallux valgus deformity in the left foot.



**Figure 2:** (a) Anteroposterior view of the dorsolumbar shows scoliosis with convexity towards the left (thick arrow) and partial fusion of upper lumbar vertebral bodies on the right side with extensive ossifications in adjacent soft tissues (thin arrow). (b) The lateral view of the cervical radiograph shows loss of normal lordosis with straightening of cervical spine curvature (thick arrow) and ossification of the interspinous ligament with the fusion of cervical spinous processes (thin arrows). (c) Oblique view of the bilateral foot with ankle radiograph shows osteopenia in visualised tarsal, metatarsal, and phalanges (thin arrow) and hallux valgus deformity in the left leg (thick arrow).

of skeletal muscle, flare-ups following viral infections, the intermittent timing of flare-ups and the beneficial response of the early flare-ups to corticosteroids support the involvement of the innate immune system in the manifestations of FOP.<sup>[8]</sup>

Madhuri *et al.*<sup>[5]</sup> reported a series of 14 patients with the FOP in which 12 patients had *P. Arg206His*. Most of these cases had bilateral hallux valgus and major heterotopic calcification in the thoracolumbar spine, shoulder and hip joints. Similar findings were noted in our case in the form of hallux valgus, metatarsophalangeal joint of the great toe and heterotopic calcification in the spine, neck, shoulder, elbow and hip region.

FOP is commonly misdiagnosed as aggressive juvenile fibromatosis, mixed connective tissue disorder (MCTD), lymphedema or soft-tissue sarcoma.<sup>[9]</sup> We considered the possibilities of bone tumours, congenital muscular dystrophy, arthrogyrosis multiplex congenital, scleroderma and MCTD. We ruled out neuromuscular problems as the child had normal power and preserved deep tendon reflexes. MCTD and scleroderma were also unlikely as there was no fever, arthritis and normal inflammatory markers.

A heterozygous missense variation in exon 6 of the *ACVR1* gene (chr2: g.158630626C>T) that results in the amino acid substitution of Histidine for Arginine at codon 206 (*P. Arg206His*) was noted. The observed variation lies in the transforming growth factor-beta type I GS-motif domain of the *ACVR1* protein and was previously reported.<sup>[5]</sup>

The median lifespan is approximately 40 years of age. Most patients are wheelchair-bound by the end of the second decade of life and commonly die of complications of thoracic insufficiency syndrome.<sup>[10]</sup> We managed the child conservatively with symptomatic treatment. We advised avoiding intramuscular injections, changing intramuscular injections to subcutaneous routes whenever possible and aggressive management of febrile illnesses. Genetic testing of the *ACVR1* gene should be considered rather than biopsy to confirm the diagnosis as a biopsy can cause new lesions.

## CONCLUSION

The FOP should be considered in children presenting with progressive stiffness, deformity of the feet and ectopic ossifications to avoid misdiagnosis and inappropriate treatment.

## Declaration of patient consent

The authors certify that they have obtained all appropriate patient consent.

## Financial support and sponsorship

Nil.

## Conflicts of interest

There are no conflicts of interest.

## REFERENCES

1. Bauer KH, Bode W. Erbpathologie der stützgewebe beim menschen. In: Bauer KH, Bode W, editors. Erbpathologie Körperliche Zustände and Funktionen. Vol. 1. Berlin: Springer Verlag; 1940. p. 105. Quoted by McKusick (1972).
2. Shore EM, Xu M, Feldman GJ, Fenstermacher DA, Cho TJ, Choi IH, *et al.* A recurrent mutation in the BMP Type I receptor ACVR1 causes inherited and sporadic fibrodysplasia ossificans progressiva. *Nat Genet* 2006;38:525-7.
3. Shore EM, Feldman GJ, Xu M, Kaplan FS. The genetics of fibrodysplasia ossificans progressiva. *Clin Rev Bone Miner Metab* 2005;3:201-4.
4. Subasree R, Panda S, Pal PK, Ravishankar S. An unusual case of rapidly progressive contractures: Case report and brief review. *Ann Indian Acad Neurol* 2008;11:119-22.
5. Madhuri V, Santhanam M, Sugumar LK, Rajagopal K, Chibbule SK. Classical and atypical fibrodysplasia ossificans progressiva in India. *Ann Hum Genet* 2015;79:245-52.
6. Hashemi J, Shahfarhat A, Beheshtian A. Fibrodysplasia ossificans progressiva: Report of a case and review of articles. *Iran J Radiol* 2011;8:113-7.
7. Kaplan FS, Groppe J, Pignolo RJ, Shore EM. Morphogen receptor genes and metamorphogenesis: Skeleton keys to metamorphosis. *Ann N Y Acad Sci* 2007;1116:113-33.
8. Kaplan FS, Shore EM, Gupta R, Billings PC, Glaser DL, Pignolo RJ, *et al.* Immunological features of fibrodysplasia ossificans progressiva and the dysregulated BMP4 pathway. *Clin Rev Bone Miner Metab* 2005;3:189-93.
9. Kitterman JA, Kantanie S, Rocke DM, Kaplan FS. Iatrogenic harm caused by diagnostic errors in fibrodysplasia ossificans progressiva. *Pediatrics* 2005;116:e654-61.
10. Kaplan FS, Zasloff MA, Kitterman JA, Shore EM, Hong CC, Rocke DM. Early mortality and cardiorespiratory failure in patients with fibrodysplasia ossificans progressiva. *J Bone Joint Surg Am* 2010;92:686-91.

**How to cite this article:** Gowda VK, Rangaiah S, Srinivasan VM, Narayana Vamyanmane DK. A rare case of deformity: Fibrodysplasia ossificans progressiva. *Karnataka Paediatr J* 2022;37:86-9.