

Letter to the Editor

Eschar in scrub typhus

Sathvika Chandrashekara Reddy¹, Vykuntaraju K. Gowda¹, Uddhava V. Kinhal¹, Sahana M. Srinivas²

Departments of ¹Pediatric Neurology and ²Pediatric Dermatology, Indira Gandhi Institute of Child Health, Bengaluru, Karnataka, India.

***Corresponding author:**

Vykuntaraju K. Gowda,
Department of Pediatric
Neurology, Indira Gandhi
Institute of Child Health,
Bengaluru, Karnataka, India.

drknvraju08@gmail.com

Received: 28 February 2024
Accepted: 28 February 2024
Epub Ahead of Print: 24 April 2024
Published:

DOI
10.25259/KPJ_4_2024

Quick Response Code:



Dear Editor,

Rickettsial diseases are caused by a variety of obligate intracellular, Gram-negative bacteria from the genera *Rickettsia*, *Orientia*, *Ehrlichia* and *Anaplasma*.^[1] Rickettsial infections are underdiagnosed in India due to their non-specific clinical presentation.^[2] The presence of an eschar, less commonly observed in the Indian population, contributes to the diagnostic process. Therefore, we are sharing this image to create more awareness of this treatable life-threatening condition.

A 2-year-old female child presented with a fever lasting seven days and seizures on day 6 of fever. On examination, vital signs were stable, revealing three eschars: One over the mid back adjacent to the medial border of the left scapula [Figure 1a], over the back below the right scapular region [Figure 1b] and the third over the left mastoid region [Figure 1c]. On systemic examination, a Glasgow Coma Scale of 5/15, meningeal irritations, brisk deep tendon reflexes and hepatosplenomegaly were noted. Investigations revealed a total leukocyte count of 18700/mm³, haemoglobin of 10.7g/dL, platelet count of 44000/mm³, total protein of 4.2 g/dL, serum albumin of 1.8g/dL, aspartate aminotransferase of 279.3U/L, alanine aminotransferase of 123.1U/L, serum urea of 122.9 mg/dL and serum creatinine of 0.86 mg/dL. The Weil Felix test was positive for OXK (1:320). Serum and cerebrospinal fluid immunoglobulin M enzyme-linked immunosorbent assay were positive for *Orientia tsutsugamushi*. Work-up for other infections, such as dengue and malaria, was negative. The child was treated symptomatically and with oral

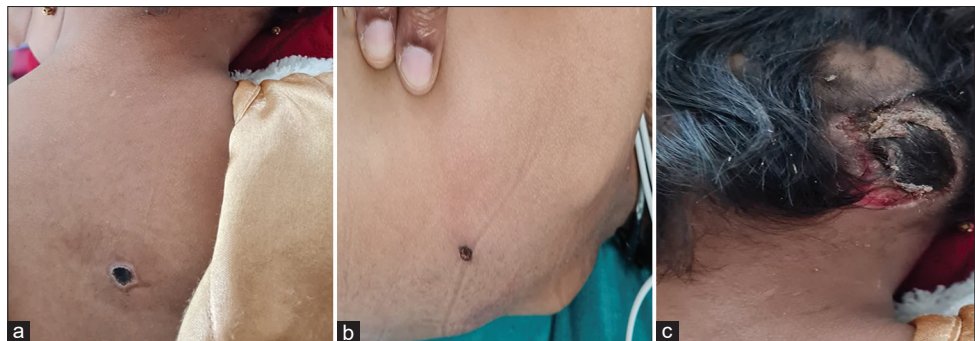


Figure 1: (a) An eschar over the mid back adjacent to the medial border of the left scapula with a black adherent crust surrounded by an erythematous halo, (b) an eschar over the back below the right scapular region with a characteristic black crust and (c) an eschar over the left mastoid region with a black necrotic crust.

This is an open-access article distributed under the terms of the Creative Commons Attribution-Non Commercial-Share Alike 4.0 License, which allows others to remix, transform, and build upon the work non-commercially, as long as the author is credited and the new creations are licensed under the identical terms.

©2024 Published by Scientific Scholar on behalf of Karnataka Paediatric Journal

doxycycline for seven days, leading to improvement in the child's condition. Rickettsial eschars are necrotic lesions that occur at the site of tick or mite bites and represent locations of primary inoculation of spotted fever group *Rickettsia* and *Orientia* species.^[3] A rickettsial eschar begins as a small, painless papule that appears within a few days after the bite of an infected vector. The papule grows, becomes vesicular or pustular and ulcerates, forming a brown-to-black crust surrounded by a red annular halo. The presence of an eschar can aid in the clinical and epidemiologic differentiation of less severe spotted fever rickettsioses from the more severe Rocky Mountain spotted fever. Rickettsial eschars serve as an important clinical specimen.^[3]

Ethical approval

The Institutional Review Board approval is not required.

Declaration of patient consent

The authors certify that they have obtained all appropriate patient consent.

Financial support and sponsorship

Nil.

Conflicts of interest

There are no conflicts of interest.

Use of artificial intelligence (AI)-assisted technology for manuscript preparation

The authors confirm that there was no use of artificial intelligence (AI)-assisted technology for assisting in the writing or editing of the manuscript and no images were manipulated using AI.

REFERENCES

1. Sood AK, Sachdeva A. Rickettsioses in children - a review. *Indian J Pediatr* 2020;87:930-6.
2. Shashidhara HJ, Augustin L. Rickettsial infection in children- clinical profile and response to treatment. *MedPulse Int J Pediatr* 2021;18:1-5.
3. Drexler N, Nichols Heitman K, Cherry C. Description of Eschar-associated Rickettsial diseases using passive surveillance data - United States, 2010-2016. *MMWR Morb Mortal Wkly Rep* 2020;68:1179-82.

How to cite this article: Reddy SC, Gowda VK, Kinhal UV, Srinivas SM. Eschar in scrub typhus. *Karnataka Paediatr J*. doi: 10.25259/KPJ_4_2024