



Case Report

Coronavirus disease 2019 associated stroke in a toddler – A case report

Nikhita Sawhney¹, Lalit Mendiratta², Neeraj Gupta¹

¹Department of Paediatrics, Sir Ganga Ram Hospital, ²Department of Paediatrics, Child Clinic and Shishu Sadan Hospital, Janakpuri, New Delhi, India.

*Corresponding author:

Neeraj Gupta,
Department of Paediatrics,
Sir Ganga Ram Hospital,
New Delhi, India.

drneeraj1979@gmail.com

Received: 21 April 2021

Accepted: 12 May 2021

Published: 30 December 2021

DOI

10.25259/KPJ_20_2021

Quick Response Code:



ABSTRACT

Background: Stroke, an infrequent entity in children, usually presents with headache, reduced cognition, and seizures as frequent findings. The association of paediatric stroke with Coronavirus disease 2019 (COVID-19) is unknown with only a hand full of postulated hypotheses till date.

Clinical Description: A 2-year-old child with sudden onset focal neurological deficits and high COVID antibody titers has been reported soon after a brief episode of cough and cold. Magnetic resonance imaging brain suggested infarct in posterior cerebral circulation. All other inflammatory markers and prothrombotic work-up were normal pointing toward a territorial affliction.

Management: Child responded well to anticoagulants (low molecular weight heparin and aspirin) with complete neurological recovery.

Conclusion: Possibility of COVID-19 associated regional endotheliitis is very high in the aforesaid toddler. Our case is the youngest reported case of paediatric stroke with a possible association with COVID-19.

Keywords: Coronavirus disease 2019, Stroke, Toddler, Endotheliitis, Endotheliopathy

INTRODUCTION

The ongoing Coronavirus pandemic has affected nearly 100 million people globally till February 10, 2021.^[1] The paediatric population at large is asymptomatic or present with mild upper respiratory and gastrointestinal symptoms only.^[2] Neurological manifestations in coronavirus disease 2019 (COVID-19) can vary from involvement of the central nervous system in form of seizures, encephalopathy, large vessel stroke, and acute necrotizing encephalitis; peripheral nervous system with Guillain-Barre syndrome such as features and skeletal muscles, as well as early alterations of olfaction and taste.^[3] In contrast to adults children show fewer neurological complications.^[4]

CLINICAL DESCRIPTION

A previously healthy 2-year-old boy had mild cough and cold 3 days before presentation. On the next day, parents noticed increased irritability in his behaviour. He was brought to the hospital as he developed outward deviation of the left eye with abnormal gait on the 3rd day of illness. There was no history of recent onset of fever, shortness of breath, skin rashes, vomiting, seizures, trauma, or vaccination. There was a history of mild fever and cough for short duration in father

This is an open-access article distributed under the terms of the Creative Commons Attribution-Non Commercial-Share Alike 4.0 License, which allows others to remix, tweak, and build upon the work non-commercially, as long as the author is credited and the new creations are licensed under the identical terms.

©2021 Published by Scientific Scholar on behalf of Karnataka Paediatric Journal

2 weeks back, who did not require any medical intervention. At admission, severe acute respiratory syndrome coronavirus 2 (SARS-CoV-2) RNA was not detected in nasopharyngeal swab. On examination, the child was irritable with left 3rd cranial nerve palsy and ipsilateral mild hemiparesis. Fundus examination was within normal limits. Magnetic resonance imaging brain and neck with angiography depicted restricted diffusion in posterior cerebral circulation suggestive of infarct with no apparent thrombus or emboli [Figure 1a and b]. 2D-Echocardiography did not reveal any thrombus or coronary artery dilatation. Pro-thrombotic investigations including lipoprotein A (19.8 mg/dL), homocysteine levels (6.85 μ mol/L), Factor V (110%), Vitamin B₁₂ (193 pg/mL), haemoglobin (10.2 g/dL), normocytic normochromic picture on peripheral smear, iron 21.3 μ mol/L, platelet count (4,23,000/ μ L), APTT (30.8 sec), INR (0.97), antithrombin activity (124%), fibrinogen (2 g/L), protein C (90.7%), and S (73.6%) activities were within normal limits. Investigations such as antinuclear antibodies, perinuclear anti-neutrophil cytoplasmic antibodies, cytoplasmic anti-neutrophil cytoplasmic antibodies, antiphospholipid antibodies, anti-proteinase 3, and myeloperoxidase for vasculitis and other rheumatological causes were unyielding. His serum COVID antibodies were high (total 234 s/c and Immunoglobulin G 18.7 s/c), which were determined by VITROS Immunodiagnostic Products anti-SARS-CoV-2 total assay, manufactured by Ortho Clinical Diagnostics. Inflammatory markers such as ferritin (10 ng/mL), interleukin-6 (1.27 pg/mL), lactate dehydrogenase (348 IU/L), C-reactive protein (negative), and NT-proBNP (31 pg/mL) were within normal limits.

MANAGEMENT AND OUTCOME

The child was started on oral aspirin (5 mg/kg/day) and low molecular weight heparin (20 units/day) subcutaneously. During the hospital stay, his irritability reduced without further progression of neurological status. He was discharged home, after 4 days of stay, on oral aspirin and rehabilitation advise. During follow-up, neurological weakness improved over next

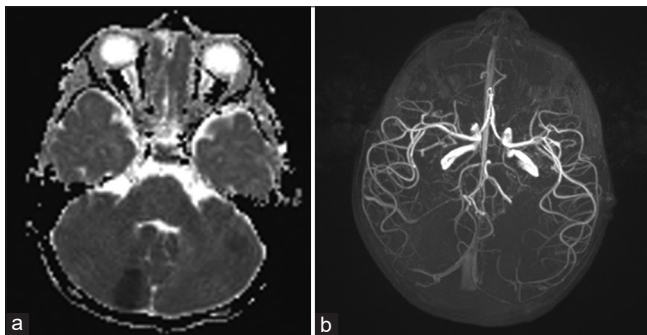


Figure 1: (a) Focal areas of restricted diffusion in midbrain and left cerebellum. (b) Normal arterial circulation.

3–4 weeks and oral aspirin was stopped after a total of 8 weeks duration. No new symptom appeared during the follow-up.

DISCUSSION

Paediatric stroke is an uncommon event with an annual incidence of 1.3–1.72 cases per 100,000 children <18 years of age.^[5] Due to the non-specific and subtle nature of symptoms most cases are frequently under-diagnosed. Acute ischemic stroke attributes to more than half of the cases most often presenting as focal neurological defect followed by headache, altered sensorium, and seizures.^[6] Our patient presented with features of cranial nerve palsy, hemiparesis, and non-specific behavioural abnormality. Common causes such as cardiac, haematological including prothrombotic states, post-infectious (influenza, HIV, hepatitis B/C, varicella, herpes simplex, and Mycoplasma), and arterio-venous malformations, metabolic states including hyperhomocystenemia, vasculitis, drugs, and trauma were ruled out. High COVID antibody titer and history of recent contact with a viral episode in father raised the possibility of COVID-19 associated neurological phenomenon in the child.

Only few cases of COVID-19 associated paediatric stroke have been reported till date.^[6] The odds of stroke is 7.6 folds higher with COVID-19 when compared to influenza.^[7] School age children have been the youngest reported cohort associated with features of systemic inflammation.^[6] Hypercoagulable state, vasculitis, and cardiomyopathy are the predominant mechanisms described for COVID-19 associated ischemic strokes.^[8] Angiotensin Converting Enzyme-2 receptors, being the entry point for SARS CoV-2, are present in endothelial and arterial smooth cells in brain, lungs, heart, small bowel, and kidneys.^[9] Direct invasion of endothelial cells is responsible for endotheliopathy, which can trigger thrombotic and inflammatory cascades through complement system activation.^[10] Viral inclusions in endothelial cells are also responsible for endothelial dysfunction and apoptosis.^[11] Endothelial dysfunction, in turn, causes vasoconstriction, organ ischemia, tissue edema, and further worsening of procoagulant state.^[12,13] Cytokine storm with hypercoagulable state can also be associated with post COVID multisystem inflammatory syndrome in children (MIS-C).^[11] Although our patient had neurological complications with high antibody titers, yet he did not complete the criteria for MIS-C as the inflammatory markers were normal and no other system was involved.^[14]

Possible pathophysiological mechanism in the index patient could be either para-infectious or immune mediated regional endotheliitis. Tissue biopsy might be of help for definite diagnosis but the feasibility and risk of intervention needs to be carefully balanced. Crippa *et al.* have found endotheliitis as probable cause of stroke in a 24-year young man associated with mild COVID-19.^[15] As per the literature search, our

patient is the youngest case to be reported till date who was affected with COVID-19 associated stroke, without any sign of systemic inflammation, with endotheliitis as probable etiology.

With the ongoing pandemic and associated increase in the number of stroke cases in paediatric population, clinicians must keep COVID-19 infection and following immune response as one of the highly suspicious causes. Large multicentre trials are needed to confirm this association. Till then an unbiased strategy should be followed to find the etiology and aggressive management should be done to avoid any neurological sequelae.

KEY MESSAGES

- Hypercoagulable states, vasculitis, and cardiomyopathy are known mechanisms for COVID-19 related stroke
- Para-infectious or immune mediated endotheliopathy is the probable etiology in the index patient
- Youngest stroke case reported with possible COVID-19 association.

CONCLUSION

A high index of suspicion for COVID-19 associated phenomenon is warranted in children presenting with clinical findings, which are otherwise unexplained during routine work-up, especially in the current pandemic era.

Declaration of patient consent

The authors certify that they have obtained all appropriate patient consent.

Financial support and sponsorship

Nil.

Conflicts of interest

There are no conflict of Interest

REFERENCES

1. World Health Organization. Coronavirus Disease (COVID-19) Outbreak Situation. Geneva: World Health Organization; 2021. Available from: <https://www.who.int/emergencies/diseases/>

2. Lu X, Zhang L, Du H, Zhang J, Li YY, Qu J, *et al.* SARS-CoV-2 infection in children. *N Engl J Med* 2020;382:1663-5.
3. Sachdev K, Agrawal S, Ish P, Gupta N, Raheja K. Neurological manifestations of COVID-19: A brief review. *Indian J Med Res* 2020;152:41-7.
4. Stafstrom CE, Jantzie LL. COVID-19: Neurological considerations in neonates and children. *Children (Basel)* 2020;7:133.
5. Mirzaee SMM, Goncalves FG, Mohammadifard M, Tavakoli SM, Vossough A. Focal cerebral arteriopathy in a COVID-19 paediatric patient. *Radiology* 2020;297:E274-5.
6. Appavu B, Deng D, Dowling MM, Garg S, Mangum T, Boerwinkle V, *et al.* Arteritis and large vessel occlusive strokes in children following COVID-19 infection. *Paediatrics* 2021;147:e2020023440.
7. Merkle AE, Parikh NS, Mir S, Gupta A, Kamel H, Lin E, *et al.* Risk of ischemic stroke in patients with coronavirus disease 2019 (COVID-19) vs patients with influenza. *JAMA Neurol* 2020;77:1-7.
8. Oxley TJ, Mocco J, Majidi S, Kellner CP, Shoirah H, Singh IP, *et al.* Large-vessel stroke as a presenting feature of COVID-19 in the young. *N Engl J Med* 2020;382:e60.
9. Carod-Artal FJ. Neurological complications of coronavirus and COVID-19. *Rev Neurol* 2020;70:311-22.
10. Magro C, Mulvey JJ, Berlin D, Nuovo G, Salvatore S, Harp J, *et al.* Complement associated microvascular injury and thrombosis in the pathogenesis of severe COVID-19 infection: A report of five cases. *Transl Res* 2020;220:1-13.
11. Spence JD, de Freitas GR, Pettigrew LC, Ay H, Liebeskind DS, Kase CS, *et al.* Mechanisms of stroke in COVID-19. *Cerebrovasc Dis* 2020;49:451-8.
12. Bonetti PO, Lerman LO, Lerman A. Endothelial dysfunction a marker of atherosclerotic risk. *Arterioscl Thromb Vas* 2003;23:168-75.
13. Varga Z, Flammer AJ, Steiger P, Haberecker M, Andermatt R, Zinkernagel AS, *et al.* Endothelial cell infection and endotheliitis in COVID-19. *Lancet* 2020;395:1417-8.
14. Jiang L, Tang K, Levin M, Irfan O, Morris SK, Wilson K, *et al.* COVID-19 and multisystem inflammatory syndrome in children and adolescents. *Lancet Infect Dis* 2020;20:e276-88.
15. Crippa S, Kägi G, Graf L, Sauteur PM, Kohler P. Stroke in a young adult with mild COVID-19 suggesting endotheliitis. *New Microbes New Infect* 2020;38:100781.

How to cite this article: Sawhney N, Mendiratta L, Gupta N. Coronavirus disease 2019 associated stroke in a toddler – A case report. *Karnataka Paediatr J* 2021;36:132-4.