



Case Report

Grave's disease in a case of Goldenhar syndrome

Neha Rajendra Shanbhag¹, S. Mruthyunjay¹, Shaila Bhattacharyya², M. N. Jayashri¹

¹Department of Pediatrics, JJM Medical College Davangere, Davangere, ²Department of Pediatric Endocrinology, Manipal Hospitals, Bengaluru, Karnataka, India.

*Corresponding author:

S. Mruthyunjay,
Professor, Department of
Pediatrics, JJM Medical
College Davangere, Davangere,
Karnataka, India.

mruthyunjay_s69@yahoo.com

Received: 03 December 2022
Accepted: 09 January 2023
Epub Ahead of Print: 10 February 2023
Published: 31 May 2023

DOI
10.25259/KPJ_33_2022

Quick Response Code:



ABSTRACT

Goldenhar syndrome (GS) is a malformation complex that involves structures arising from the first and second branchial arches. Graves' disease is an autoimmune disorder resulting in the excessive production of thyroid hormones and is the most common cause of hyperthyroidism in children. We are reporting this case since the clinical association of Graves' disease in GS has never been reported before and is a rare association of the syndrome. An 11-year-old developmentally normal child presented to us with swelling in front of her neck for the past 6 months associated with loss of weight, increased appetite, increased frequency of defecation, and palpitations. On examination, there was diffuse swelling in the thyroid region that moved with deglutition and did not move with protrusion of the tongue. The child also had an asymmetrical face with bilateral conjunctival dermoid and bilateral preauricular skin tag and pretragal sinus tract on the left side. Hence, a provisional diagnosis of goitre with features of hyperthyroidism in a child with first and second branchial arch syndrome was considered. Technetium 99 scan confirmed diagnosis of Graves' disease. The child was started on carbimazole and propranolol and gradual improvement in symptoms noted. Propranolol was given for 3 months until symptoms such as palpitations and anxiety subsided and then stopped. Carbimazole was continued.

Keywords: Goldenhar syndrome, Graves' disease, Carbimazole, Propranolol

INTRODUCTION

Goldenhar syndrome (GS) initially described by Goldenhar in 1952, later modified by Gorlin in 1963 who called it oculo-auriculo-vertebral syndrome is characterised by preauricular appendages, sinus/fistula, epibulbar dermoids and vertebral anomalies.

Graves' disease is an autoimmune disorder resulting in the production of thyroid-stimulating hormone (TSH) receptor stimulating antibodies that bind and activate G Protein coupled TSH receptor to cause thyroid hormonogenesis and diffuse glandular growth. It is the most common cause of paediatric hyperthyroidism with an incidence of 1:5000 and female predominance of 5:1.^[1] It leads to thyrotoxicosis, that is, a state of excessive circulating thyroid hormones.

CASE REPORT

An 11-year-old, developmentally normal child, the only living issue of non-consanguineous marriage, was brought with complaints of swelling in front of the neck since 6 months [Figure 1]. The swelling was initially of size 1 × 1 cm and gradually increased to 10 × 15 cm at the time of association. Furthermore, the child had a history of increased appetite and loss of weight since

This is an open-access article distributed under the terms of the Creative Commons Attribution-Non Commercial-Share Alike 4.0 License, which allows others to remix, transform, and build upon the work non-commercially, as long as the author is credited and the new creations are licensed under the identical terms.

©2023 Published by Scientific Scholar on behalf of Karnataka Paediatric Journal

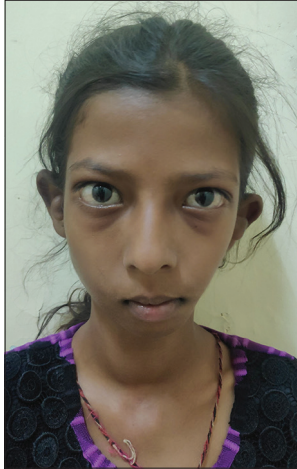

Figure 1: Goldenhar syndrome with anterior neck swelling.

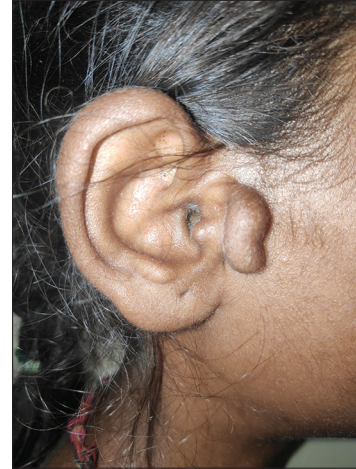

Figure 3: Preauricular skin tag and accessory tragus.

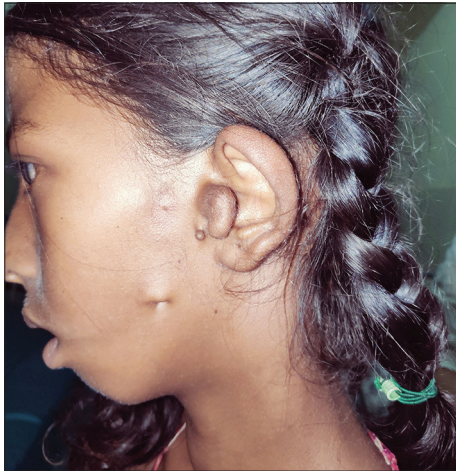

Figure 2: Left sided sinus tract, left preauricular pit, accessory tragus and preauricular skin tag.

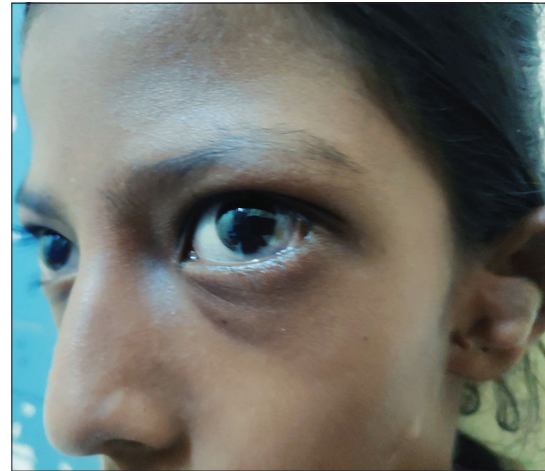

Figure 4: Epibulbar dermoid.

6 months. As per school weight records, the child had lost 5 kg weight since 6 months.

The mother had noticed reduced concentration and a decline in the scholastic performance of the child for 3 months. She also had a history of increased tremulousness, palpitations, disturbed sleep with easy awakening, and increased anxiety. However, the swelling has never caused difficulty in breathing or a change in voice in the child.

On asking about the look of the child (asymmetry of face with skin tags), the mother said that they have never consulted previously regarding the same as they found it normal. Father and paternal great-grandmother also have skin tags in front of the ear on one side, but not other syndromic features as that of the child. She had no history of previous hospitalisation. There is no history of significant antenatal, natal or postnatal events during pregnancy. However, the mother has a history of the previous two intrauterine deaths (cause of which is not

known) and previous 1 spontaneous abortion at 4 months of gestation. The child is developmentally normal, vaccinated as per the national immunisation schedule and consuming an excessive of 900 Calories/day.

At the time of admission, the child was afebrile, had tachycardia – with resting pulse rate of 120 beats/min and sleeping pulse rate of 108 beats/min, regular rhythm, normal volume, respiratory rate of 18 breaths/min, saturation of 95–96% in all four limbs and blood pressure, which was 100/64 mmHg (50–90th centile). Anthropometry was done – the height of the child was at 50th centile (142 cm), whereas weight was <3rd centile (19 kg; expected is 34 kg) and body mass index of 9.92 kg/m² (<3rd centile).

On examining the child from head to toe, it was noted that the child had a syndromic appearance with asymmetrical facies and sinus at 3 cm in front of the left ear [Figure 2].

The child had bilateral preauricular skin tags, with an additional preauricular pit on the left side [Figure 3]. Other

parts of the ear were structurally normal. The child also had a high arch palate and micrognathia.

Bilateral lid retraction presents. A bilateral conjunctival dermoid is shown [Figure 4]. The child had all signs of thyrotoxicosis, that is, staring look (Stellwag positive), there was lid lag on looking down (Von Graeffe positive) and there was an absence of wrinkling on looking up (Joffrey's sign positive). There was a failure of convergence of eyeballs (Mobius positive), upper sclera was visible, and no signs of chemosis. Child had normal vision. Tongue tremors were present.

On examining the neck, it was observed that the child had swelling of size 10 × 5 cm, was firm in consistency, and had rounded borders that moved with deglutition but did not move with protrusion of the tongue. Pemberton's method was positive, carotid pulsations were prominent.

On palpation, the child was found to have ill formed mandible on the left side (hypoplasia). Neck swelling was non-tender with a smooth surface, firm in consistency with palpable bruit. Signs of Horner's syndrome such as miosis, enophthalmos, pseudoptosis or anhidrosis were absent.

An audible bruit was present all over the thyroid region.

As the child looked syndromic, with complaints of swelling in the thyroid region and symptoms of thyrotoxicosis, a provisional diagnosis of diffuse goitre with thyrotoxicosis in a syndromic child was considered and relevant investigations were sent.

Management and outcome-

Preliminary investigations were done and were as follows:

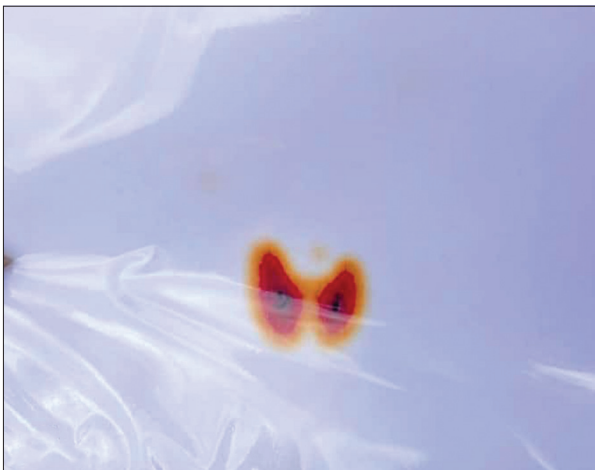


Figure 5: Tc 99 scan shows increased trapping function by enlarged thyroid with no definite hot or cold areas-Grave's pattern.

Haemoglobin	13.4 g/dL
Total count	8820 cells/mm ³
Differential counts	Neutrophils 54% Lymphocytes 42%
Thyroid stimulating hormone	<0.01 μIU/mL
Free T3	>30 pg/mL
Free T4	>6.11 ng/dL

Ultrasonography of swelling was suggestive of thyroiditis with grade 4 vascularity.

Based on the above reports, the differential diagnosis for hyperthyroidism was Graves' disease/Toxic Nodular Goitre (TNG)/McCune Albright syndrome. As on palpation, there was no nodule felt, and TNG was clinically ruled out. As there was no history of precocious puberty or neurocutaneous markers like café au lait spots, McCune Albright syndrome was clinically ruled out. Thyroid Technetium 99 scan was done that confirmed the diagnosis of Graves' disease [Figure 5].

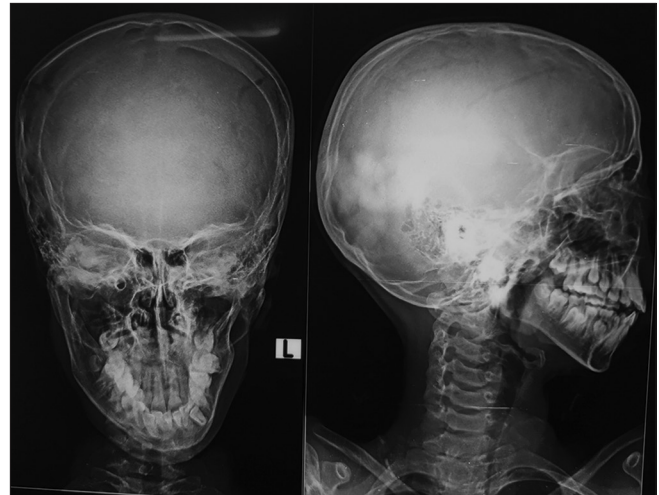


Figure 6: X-ray skull and face showing left mandibular hypoplasia.

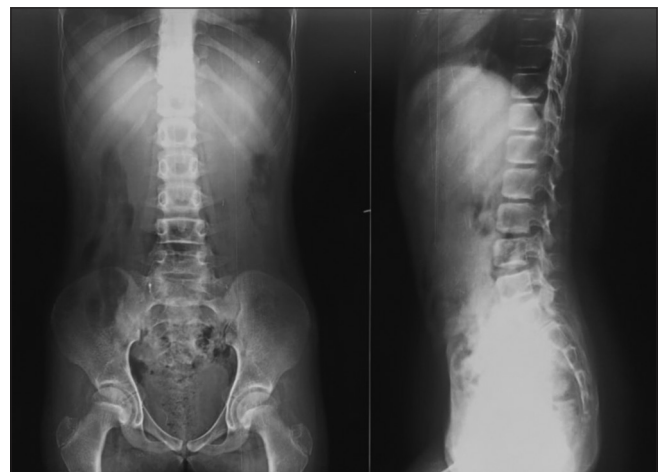


Figure 7: X-ray spine showing lumbarisation of first sacral vertebra.

As for the syndromic features of the child, a differential diagnosis of first branchial arch syndrome/GS/hemifacial microsomia/Pierre Robin syndrome/Treacher Collin syndrome was considered.

X-ray skull confirmed mandibular hypoplasia on the left side [Figure 6]. X-ray spine showed lumbarisation of the first sacral vertebra [Figure 7]. As the child had preauricular skin tags, pre-tragal blind ended sinus, epibulbar dermoid and vertebral anomaly-all features fit into GS and hence the diagnosis.

Paediatric endocrinologist's opinion was taken and the child was started on the antithyroid drug Carbimazole at a dose of 0.5 mg/kg/day in two divided doses for 2 weeks later tapered to the maintenance dose of 0.3 mg/kg/day. The child was also started on propranolol for supportive management. Propranolol was given at a dose of 0.5 mg/kg/day for 3 months until symptoms such as palpitations and anxiety subsided and, thereafter, were stopped. However, carbimazole has been continued. Free T4 was repeated and had dropped from >6.11 ng/dL to 0.83 ng/dL within 1 month of starting treatment; however, there was no difference in TSH noted.

Parents were also counselled regarding the syndromic condition of the child, and that the syndrome *per se* has a good prognosis. Option of cosmetic correction of the face by sinus tract and skin tag excision, jaw reconstruction was given to the parents, but they did not opt for the same.

DISCUSSION

GS is included in the broader diagnostic category of oculo-auriculo-vertebral syndrome by Gorlin *et al.*^[2] The exact aetiology is not known. The estimated occurrence in first degree relatives is approximately 2%, although minor features of this disorder may be noted in relatives.^[2] In this case, the father and paternal great grandmother had preauricular skin tags but no other features of GS. Mckenzie described the pathogenesis of first branchial arch syndrome as insufficient oxygen supply by the stapedia artery during the embryonic development of the first branchial arch.^[3]

In GS, ocular anomalies especially bilateral dermoids are seen in 60% of cases, vertebral anomalies are seen in 40% of cases, and other ear anomalies are seen in 40% of cases.^[4]

In GS, auricular or preauricular appendages are the most important constant feature, which are usually bilateral and multiple as seen in our case. Epibulbar dermoids are the most common ophthalmic manifestation of GS. Microphthalmia, microcornea, coloboma of eyelids, iris atrophy and polar cataract have been reported.^[5,6]

Oral manifestations include high arch palate and micrognathia that were present in our case. Other features reported are cleft lip, cleft palate, diminished to absent parotid secretion,

ankyloglossia, and upper alveolar notching which have been reported,^[7,8] but these features were not seen in our case.

According to a study done by Schroeder *et al.*, 64% of branchial arch anomalies presented with a lateral neck mass.^[9] However, interestingly, in this case, we had neck mass anteriorly due to thyroid gland enlargement, secondary to Graves' disease.

Graves' disease is the most common cause of paediatric hyperthyroidism. It is an autoimmune disorder resulting in the production of Thyrotropin (TSH) receptor stimulating antibodies causing increased thyroid hormonogenesis. Enlargement of the thymus, splenomegaly, lymphadenopathy, peripheral lymphocytosis, and infiltration of the thyroid gland and retro-orbital tissues with lymphocytes and plasma cells are well established findings in Graves' disease. The ophthalmopathy that occurs in Graves' disease is caused by antibodies shared by both the thyroid and retro-orbital tissue. Our patient had all signs of Grave's ophthalmopathy.

As this child had features of hyperthyroidism due to Graves' disease, she was started on carbimazole – an anti-thyroid drug. Paediatric endocrinologists prefer medical treatment with antithyroid drugs such as carbimazole or methimazole as an initial line of management. They act by inhibiting the organification of iodide needed for thyroid hormone production. In a few centres, Radioiodine is preferred in children >10 years. Surgical management with near total thyroidectomy can be the last resort.

Treatment options for Goldenhar *per se* includes cosmetic correction, that is, excision of preauricular skin tags, excision of sinus tract, jaw reconstruction, and excision of epibulbar dermoids. Counselling the child and family regarding the syndrome and giving psychological support for social attributes should be done.

CONCLUSION

The association of Graves' disease in GS is being reported for the first time in literature. Counseling the child and family regarding the syndrome and giving psychological support for social attributes is important.

Declaration of patient consent

The authors certify that they have obtained all appropriate patient consent.

Financial support and sponsorship

Nil.

Conflicts of interest

There are no conflicts of interest.

REFERENCES

1. Kliegman RM. Nelson Textbook of Pediatrics. 21st ed. Philadelphia, PA: Elsevier; 2020.
2. Gorlin RJ, Jue KL, Jacobsen U, Goldschmidt E. Oculoauriculovertebral dysplasia. *J Pediatr* 1963;63:991-9.
3. Mekenzie J. The first arch syndrome. *Arch Dis Child* 1958;33:477-86.
4. Nakajima H, Goto G, Tanaka N, Ashiya H, Ibukiyama C. Goldenhar syndrome associated with various cardiovascular malformations. *Jpn Circ J* 1998;62:617-20.
5. Gathwala G, Tiwari AD, Singh I, Yadav SP. Goldenhar syndrome. *Indian J Pediatr* 1992;59:770-2.
6. Baum JL, Feingold M. Ocular aspects of Goldenhar's syndrome. *Am J Ophthalmol* 1973;75:250-7.
7. Jones KL, Jones MC, Campo MD, Smith DW. Smith's Recognizable Patterns of Human Malformation. 7th ed. Philadelphia, PA: Elsevier Saunders; 2013;832-3.
8. Kumar R, Balani B, Patwari AK, Anand VK, Ahuja B. Goldenhar syndrome with rare associations. *Indian J Pediatr* 2000;67:231-3.
9. Schroeder JW Jr, Mohyuddin N, Maddalozzo J. Branchial anomalies in the pediatric population. *Otolaryngol Head Neck Surg* 2007;137:289-95.

How to cite this article: Shanbhag NR, Mruthyunjay S, Bhattacharyya S, Jayashri MN. Grave's disease in a case of Goldenhar syndrome. *Karnataka Paediatr J* 2023;38:16-20.