



Case Report

The company that one keeps: An interplay between growth hormone and other pituitary hormones

Diksha Shirodkar¹, Najya Nasrin¹, Safeena Ansari Suhara¹, Prakash Robert Mario Saldanha¹

¹Department of Paediatrics, Yenepoya Medical College and Hospital, Mangalore, Karnataka, India.

*Corresponding author:

Diksha Shirodkar,
Assistant Professor (Paediatrics)
and Paediatric Endocrinologist,
Department of Paediatrics,
Yenepoya Medical College
and Hospital, Mangalore,
Karnataka, India.

shirodkardikshas@gmail.com

Received: 11 March 2022
Accepted: 07 May 2022
EPub Ahead of Print: 20 June 2022
Published: 16 November 2022

DOI
10.25259/KPJ_3_2022

Quick Response Code:



ABSTRACT

Short stature is defined as a height <2 SD from the mean height for a child of the same sex, ethnicity and chronological age. We present a case series of proportionate short stature whose associated endocrinological deficits left us intrigued. A 9 ½-year-old boy presented with poor growth-velocity (GV) for 5 years and central diabetes insipidus (on the treatment for 1 year). His height was 118 cm (-2.6 SD) and his weight was 20 kg (-2.03 SD). MRI brain showed hypoplastic anterior pituitary with absent bright spot and growth hormone (GH) dynamics proved GH deficiency. A 10-year-4-month-old girl presented with poor GV. Her height was 106 cm (-4.44 SD) and her weight was 15 kg (-3.74 SD). Targeted investigations revealed multiple pituitary hormone deficiencies (central hypothyroidism, secondary adrenal insufficiency and GH deficiency). MRI brain showed reduced pituitary height with ectopic posterior pituitary. GH therapy commenced only after coverage with hydrocortisone. A 1-year-old boy was admitted with failure to gain weight and height for 4 months of age. His length was 57 cm (-7.89 SD) and weight: was 4.6 kg (-5.86 SD) with immature facies, frontal bossing and midfacial hypoplasia. Low GH values at the time of critical sample (blood glucose = 36 mg/dl) revealed GH deficiency. MRI brain demonstrated a hypoplastic pituitary gland. All proportionate short-statured children without obvious dysmorphism need detailed evaluation. GH deficiency can present as a spectrum from isolated deficiency to multiple pituitary (anterior and posterior) deficiencies and so the order of correction of the deficiencies is equally important.

Keywords: Growth hormone deficiency, Combined pituitary hormone deficiency, Short stature, Central diabetes insipidus, Central hypothyroidism

INTRODUCTION

Short stature is defined as height $<3^{\text{rd}}$ percentile for the mean age and sex of the child or poor growth-velocity (GV) relative to sex and bone-age matched peers or height <1.5 Z-scores from the mean for the mid-parental height.^[1] The aetiology for proportionate short stature includes genetic, prenatal, postnatal and environmental causes. In developing countries, failure to thrive is usually due to nutritional causes. Prompt identification and treatment of these children will help in reducing the excessive short stature in adulthood. We present a case series of short stature whose aetiology left us amazed.

CASE REPORTS

Case 1

A 9 ½-year-old boy presented with short stature for 5 years, polyuria and polydipsia for 3 years of age (treated with desmopressin for the central diabetes insipidus). He had infantile facies

This is an open-access article distributed under the terms of the Creative Commons Attribution-Non Commercial-Share Alike 4.0 License, which allows others to remix, transform, and build upon the work non-commercially, as long as the author is credited and the new creations are licensed under the identical terms.

©2022 Published by Scientific Scholar on behalf of Karnataka Paediatric Journal

with a protuberant belly [Figure 1d]. He was prepubertal with a height: 118 cm {(-2.6 z-score), height age = 6.6 years}, weight: 20 kg {(-2.03 Z-score), weight age = 6.3 years} and a bone-age (Radius-ulna-staging Tanner-Whitehouse III method {RUSTWIII}) of 6.9 years. Growth hormone deficiency (GHD) surfaced when the GH stimulation test was performed using clonidine [Table 1]. The peak value demonstrated was 1.69 ng/dl at 90 min. MRI brain showed a reduced pituitary height [Figure 1a]. He was started on GH therapy and is currently growing well.

Case 2

A 10 year and 4 months old girl was admitted with poor growth for 2 years. She had infantile facies, a high pitched voice and intact primary dentition [Figure 1e]. She was prepubertal, weight = 14 kg (-4.02 SDS), height = 104 cm (-4.71 SDS) and bone age of 5.5 years. She was having central hypothyroidism and hypocortisolism. MRI brain showed a hypoplastic pituitary with ectopic posterior pituitary [Figure 1b]. After euthyroidism and eucortisolemia were established, a GH stimulation test (using clonidine) was done

which demonstrated very low stimulated GH values, the peak value being 1.09 ng/ml at 0 min [Table 1] and hence GH therapy was initiated. She responded dramatically with a GV of 6 cm/6 months.

Case 3

A 1-year-old boy was brought with failure to thrive. He was a term child with a birth weight of 2.7 kg. Birth length was not recorded and the postnatal events were uneventful. The child was exclusively breastfed till 6 months and then complementary feeding started which the child was accepting satisfactorily. On examination, he had frontal bossing, two maxillary incisors and apparent macrocephaly [Figure 1f]. His weight = 4.7 kg (-5.86 z-score), length = 56 cm (-7.89 Z-score) and bone-age of 1 year. MRI brain showed reduced pituitary height [Figure 1c]. GH stimulation testing using glucagon was planned (considering the age) but overnight fasting led to hypoglycaemia (36 mg/dl) and the critical sample showed markedly decreased GH (0.003 ng/ml), IGF-1 (<15 ng/dl) and insulin-like-growth-factor-1-binding- protein-3 of <0.5 µg/ml

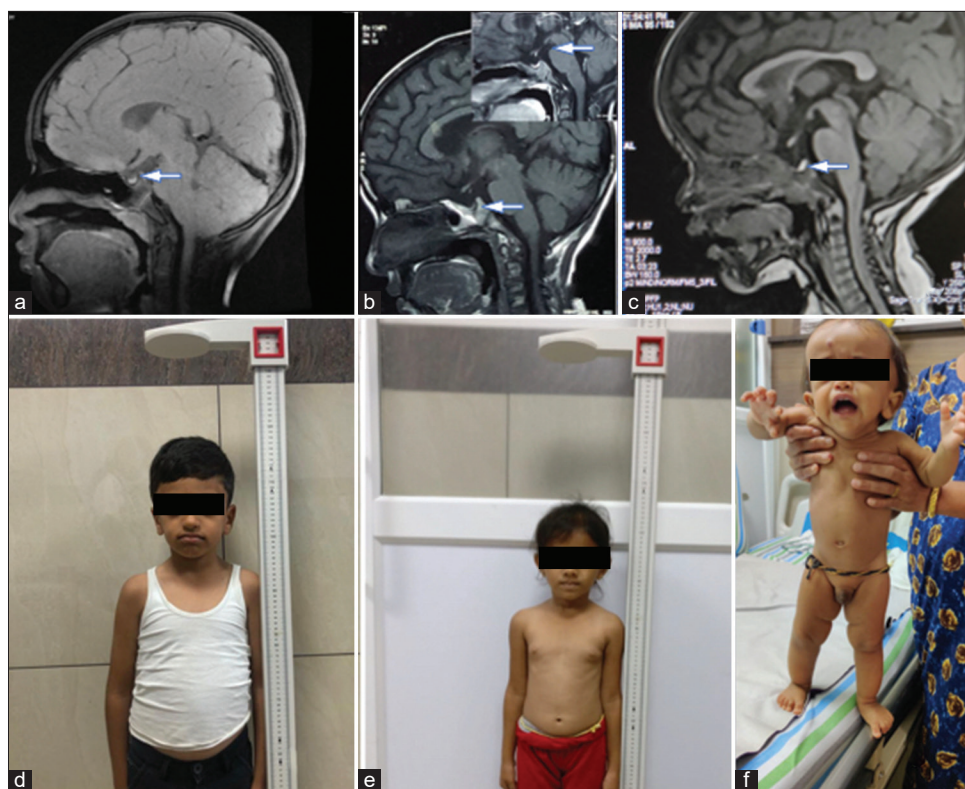


Figure 1: (a) MRI brain T1-weighted sagittal view of Case 1, showing hypoplastic pituitary (0.4 × 1.2 × 0.53 cm), normal stalk and absent pituitary bright spot (white arrow). (b) MRI brain T1-weighted sagittal view of Case 2, showing hypoplastic pituitary (1 × 0.6 × 0.7 cm) and ectopically located posterior pituitary bright spot along the stalk (white arrow). The magnified view on the right upper corner of the image. (c) MRI brain T1-weighted sagittal view of Case 3 showing reduced pituitary size (maximum height 3 mm) with normal posterior pituitary and stalk (white arrow). (d) Image of Case 1 showing the infantile facies, protuberant belly and height deficit. The expected height is shown on the movable head end of the stadiometer. (e) Image of Case 2 showing infantile facies and the short stature. The expected height is shown on the movable head end of the stadiometer. (f) Image of Case 3 showing apparent macrocephaly, frontal bossing and infantile facies.

Table 1: Investigations of the cases.

Investigations	Case 1	Case 2	Case 3	Normal values
Thyroid-stimulating hormone (mIU/ml)	3.56	0.055	3.62	0.57–5.54
Free T4 (ng/dl)	1.57	1.2	1.14	1.10–2.2
Serum cortisol (µg/dl)	6.99	2.7	31.6	3–21
Fasting blood glucose (mg/dl)	85	90	36	70–110
Tissue transglutaminase antibody- IgA (U/ml)	<0.200	0.278	1.14	<4 – Negative
Fasting insulin-like-growth-factor-1-binding-protein-3 (µg/ml)	Not afford-	ing	Not afford-	At 1 year: 0.7–3.6
Fasting IGF-1 (ng/ml)	25	50.8	<15	1 year boy:18–179 9–10 years boy: 58–401 10–11 years girl: 83–465
Serum osmolality (mosm/kg water)	261	No polyuria/ polydipsia	No polyuria/ polydipsia	275–294
Urine osmolality (mosm/kg water)	113			500–850
GH (ng/ml)				
0 min	0.41	1.09	<0.003 at the time of hypoglycaemia (36 mg/dl)	<10 ng/ml is suggestive of Growth hormone deficiency
30 min	0.42	0.389		
60 min	1.14	0.970		
90 min	1.69	0.633		
120 min	1.05	0.854		

[Table 1]. Considering the diagnosis to be GHD, GH therapy commenced at 0.016 mg/kg/week. The response was dramatic and the child is currently growing well (GV 6 cm in 3 months).

DISCUSSION

Growth is a complex process in which nutrition, hormones, genetic factors and environmental factors play a major role. GH-IGF-I axis is the most important factor. GHD can be isolated (IGHD) or associated with at least one other pituitary hormone deficiency called CPHD. The clinical presentation is of varying nature, depending on the type and severity of GHD, the age at diagnosis and the association with other pituitary hormone deficiencies or brain malformations. The genes involved in IGHD include GH1, GH-releasing-hormone-receptor and transcription factor SOX3. There are three types of IGHD depending on the genes involved, namely, Type I (severe short stature), Type II (hypoplastic pituitary occasionally and progression to CPHD) and Type III (X linked with/without mental retardation and ectopic posterior pituitary).^[2,3] CPHD is a complex phenotype including anterior pituitary hormone deficiencies in association with extra pituitary abnormalities or congenital malformations, for example, pituitary stalk interruption syndrome. Acquired GHD is idiopathic usually or due to lesions in the anterior pituitary, pituitary stalk/hypothalamus (craniopharyngioma), radiotherapy, chemotherapy, brain trauma, pituitary inflammation/infection/infarction and psychosocial deprivation.^[4] The gold standard for diagnosing GHD is GH stimulation testing with two stimuli.

Random GH levels are of no value due to the pulsatile nature of GH secretion. Children with any of the following features should be evaluated: Short stature with a height <2 Z-scores from the mean, height which does not correspond to the familial background and a significant decrease in the growth velocity that is not explained by the normal physiology.^[5] Certain clues for GHD are hypoglycaemia with midline defects, exaggerated neonatal jaundice, micropenis, single incisor, etc. There is a risk of progression from IGHD to CPHD, especially in children having GHD with a significant pituitary gland anomaly. The dynamics of pituitary hormone deficiencies can range from mild to severe and can develop over some time.^[6] After GH, TSH is the next hormonal deficit to occur with a prevalence of 6.3% during the first 2 years of treatment.^[7] An unsatisfactory increase of IGF-1 and a low GV to GH treatment are signs of evolving TSH deficiency.^[7] Risk factors for CPHD are malformations of the pituitary-hypothalamic region and acquired GHD. Anti-diuretic hormone (ADH) deficiency very rarely evolves after the diagnosis of IGHD and the opposite is usually true^[8] like in Case 1. In the presence of GHD, ADH deficiency may be associated with septo-optic dysplasia or acquired causes (pituitary surgery, infundibulitis, tumours, histiocytosis and head trauma).^[9] Therefore, one needs to have a hawk's eye to look for the above causes if there is a DI in children with IGHD.

CONCLUSION

This case series enlightens about how short stature in a developing country should not always be attributed to a familial cause or poor nutritional status. The drawback here was the lack of establishing a genetic diagnosis, but this was

purely due to financial constraints. GHD was the cause in all three cases but more important was looking for other pituitary hormonal deficits which, like in Case 2, made us alert and timed sequential management made us avert an adrenal crisis.

Acknowledgment

Authors wish to thank all the three patients and their guardians.

Declaration of patient consent

The authors certify that they have obtained all appropriate patient consent.

Financial support and sponsorship

Nil.

Conflicts of interest

There are no conflicts of interest.

REFERENCES

1. Growth Hormone Research Society. Consensus guidelines for the diagnosis and treatment of growth hormone (GH) deficiency in childhood and adolescence: Summary statement of the GH research society. *J Clin Endocrinol Metab* 2000;85:3990-3.
2. Alatzoglou KS, Dattani MT. Genetic causes and treatment of isolated growth hormone deficiency an update. *Nat Rev Endocrinol* 2010;6:562-76.
3. Castinetti F, Reynaud R, Quentien MH, Jullien N, Marquant E, Rochette C, *et al.* Combined pituitary hormone deficiency: Current and future status. *J Endocrinol Invest* 2014;38:1-12.
4. Dattani MT, Malhotra N. A review of growth hormone deficiency. *Paediatr Child Health* 2019;29:285-92.
5. Collett-Solberg P, Ambler G, Backeljauw PF, Bidlingmaier M, Biller BM, Boguszewski MC, *et al.* Diagnosis, genetics, and therapy of short stature in children: A growth hormone research society international perspective. *Horm Res Paediatr* 2019;92:1-14.
6. Binder G, Schnabel D, Reinehr T, Pfäffle R, Dörr HG, Bettendorf M, *et al.* Evolving pituitary hormone deficits in primarily isolated GHD: A review and experts' consensus. *Mol Cell Pediatr* 2020;7:16.
7. van Iersel L, van Santen HM, Zandwijken GR, Zwaveling-Soonawala N, Hokken-Koelega AC, van Trotsenburg AS. Low FT4 concentrations around the start of recombinant human growth hormone treatment: Predictor of congenital structural hypothalamic-pituitary abnormalities? *Horm Res Paediatr* 2018;89:98-107.
8. Di Iorgi N, Allegri AE, Napoli F, Calcagno A, Calandra E, Fratangeli N, *et al.* Central diabetes insipidus in children and young adults: Etiological diagnosis and long-term outcome of idiopathic cases. *J Clin Endocrinol Metab* 2014;99:1264-72.
9. Yang YH, Lin JJ, Hsia SH, Wu CT, Wang HS, Hung PC, *et al.* Central diabetes insipidus in children with acute brain insult. *Pediatr Neurol* 2011;45:377-80.

How to cite this article: Shirodkar D, Nasrin N, Suhara SA, Saldanha PR. The company that one keeps: An interplay between growth hormone and other pituitary hormones. *Karnataka Paediatr J* 2022;37:51-4.