




Case Report

Treatable and non-treatable neuroregression in the same child: A rare case of GM1 gangliosidosis with infantile tremor syndrome-ITS

Vykuntaraju K. Gowda¹, Varsha Manohar¹ , Varunvenkat M. Srinivasan¹, Dhananjaya Kotebagilu Narayana Vamyanmane² 

Departments of ¹Pediatric Neurology and ²Pediatric Radiology, Indira Gandhi Institute of Child Health, Bengaluru, Karnataka, India.

*Corresponding author:

Vykuntaraju K. Gowda,
Department of Pediatric
Neurology, Indira Gandhi
Institute of Child Health,
Bengaluru, Karnataka, India.

drknvraju08@gmail.com

Received : 19 March 2023

Accepted : 23 March 2023

Published : 10 May 2023

DOI

10.25259/KPJ_12_2023

Quick Response Code:



ABSTRACT

GM1 gangliosidosis is an autosomal recessive lysosomal storage disease caused by a deficiency of acid β -galactosidase. Infantile tremor syndrome (ITS) in infants presents with progressive neurological deterioration. We present a rare case of an Indian-origin child with neuroregression presenting with both reversible (ITS) and irreversible causes (GM1 gangliosidosis) in the same child. A 10-month-old boy born to a consanguineously married couple, presented with developmental delay followed by regression. On examination, sparse hypopigmented hair and coarse facial features were noted. On investigations, haemoglobin was 7.9 g/dL, megaloblastic picture, macro-ovalocytes change in the peripheral smear, vitamin B12-170 pg/mL (211-711), increased homocysteine level-72 μ mol/L (normal 5-15) and low β galactosidase-1.4 (15.0-285.0) level. Exome sequencing revealed homozygous likely pathogenic missense variant c. 266A>T (p.His89Leu) in exon 3 of *GLB1* gene, thus confirming the diagnosis of GM1 gangliosidosis with vitamin B12 deficiency. Here is a rare case of neuroregression presenting with both reversible ITS and irreversible causes of GM1 gangliosidosis in the same child, so one should consider simple treatable causes when diagnosed with neurodegenerative disorders to improve the outcome.

Keywords: GM1 gangliosidosis, Vitamin B12 deficiency, Infantile tremor syndrome, India

INTRODUCTION

GM1 gangliosidosis is an inherited disorder caused by a deficiency of acid β -galactosidase that progressively destroys neurons in the brain and spinal cord. In this autosomal recessive lysosomal storage disease, there is a deficiency of acid β -galactosidase due to a mutation in the *GLB1* gene.^[1] Infantile tremor syndrome (ITS) presents with progressive neurologic deterioration, irritability, failure to thrive, apathy and anorexia, accompanied by the consistent refusal of solid foods.^[2] We present an infant with GM1 gangliosidosis with vitamin B12 deficiency.

CASE REPORT

A 10-month-old boy born to a consanguineously married couple, presented with developmental delay followed by regression on already attained milestones such as social smile, recognition of the mother and bi-dextrous approach since the past 2 months. The mother is a strict vegetarian and the child was exclusively breastfed for 8 months of life and started weaning with ragi malt

This is an open-access article distributed under the terms of the Creative Commons Attribution-Non Commercial-Share Alike 4.0 License, which allows others to remix, transform, and build upon the work non-commercially, as long as the author is credited and the new creations are licensed under the identical terms.

©2022 Published by Scientific Scholar on behalf of Karnataka Paediatric Journal

twice a day. On examination, the child's weight was 9.8 kg, the occipitofrontal circumference was 49 cm (+3 SD), sparse hypopigmented hair, coarse facial features, frontal bossing, depressed nasal bridge, hypertelorism, bilateral macular cherry-red spots, gingival hypertrophy, hyperpigmentation of knuckles, bilateral lower limb pitting oedema, kyphosis, extensive Mongolian spots over the lower back, hepatosplenomegaly, generalized hypotonia and tremors [Figure 1a-c].

On investigations, haemoglobin was 7.9 g/dL, megaloblastic picture, macro-ovalocytes change in the peripheral smear, vitamin B12-170 pg/mL (211-711), increased homocysteine level-72 $\mu\text{mol/L}$ (normal 5-15) and low β -galactosidase-1.4 (15.0-285.0) level. Magnetic resonance imaging brain revealed bilateral thalamus signal changes with delayed myelination for age [Figure 1d]. The mother's investigations showed megaloblastic anaemia (haemoglobin - 9 g/dL), with a low B12 level (120 pg/mL). Exome sequencing revealed homozygous likely pathogenic missense variant c. 266A>T (p.His89Leu) in exon 3 of *GLB1* gene, thus confirming the diagnosis of GM1 gangliosidosis with vitamin B12 deficiency. With intravenous vitamin B12 1000 mcg, improvement in development, skin and hair changes and haemoglobin increased to 10.5 g/dL and homocysteine level decreased to 12 $\mu\text{mol/L}$.

DISCUSSION

To summarize, we report a child with GM1 gangliosidosis with clinical, biochemical features of ITS. Beta-galactosidase is a lysosomal hydrolase enzyme involved in the metabolism of sphingolipid GM1 ganglioside. The deficiency of this enzyme leads to impaired metabolism of lactosyl-ceramide, terminal b-linked galactose contacting oligosaccharides and keratin sulphate to variable extents. The accumulated toxic sphingolipid intermediates hamper lysosomal homeostasis.

Neurodegeneration is a hallmark as maximum ganglioside metabolism occurs in the nervous system.^[3]

Lysosomes are also involved in the metabolism of vitamin B12. The holotranscobalamin containing B12 is internalized through receptor-mediated endocytosis. The B12 then reaches lysosomes where transcobalamin is cleaved and B12 is released. The B12 is exported out of lysosomes through transporters LMBRD1 and ABCD4. Mutations in the ABCD4 gene cause methylmalonic aciduria and homocystinuria, cblj type; mahcj [OMIM#614857] and mutations in the LMBRD1 gene cause methylmalonic aciduria and homocystinuria, cblf type; mahcf [OMIM#277380] and both these constitute an inborn error of B12 metabolism due to lysosomal form.^[4-7] The neurological features of vitamin B12 deficiency may be variable from tone changes, alteration in mutation and sometimes coma. Neuroregression with vitamin B12 deficiency is reported.^[8]

Theoretically, lysosomal storage disorders can have deficient vitamin B12 as the B12 metabolism requires lysosomes as previously described. A 2-year prospective study on patients with Gaucher disease type 1 (GD) on enzyme replacement treatment (ERT) with and without polyneuropathy showed elevated homocysteine and methylmalonic acid in the polyneuropathy group, but both groups showed low-normal vitamin B12 values. This study shows an association between GD and vitamin B12 deficiency.^[9] However, the clinical translation awaits further studies. Another study that examined the overall vitamin B12 metabolism status in GD skin fibroblasts versus control showed preserved metabolism of B12 despite the lysosomal storage of glucocerebroside. The study concluded that the presence of a deficiency of vitamin B12 in GD patients requires an individual case-based approach. The study however did not study B12 metabolism in other cell types and needs further studies.^[10] However, no reports exist on linking GM1 gangliosidosis to vitamin B12 defect.

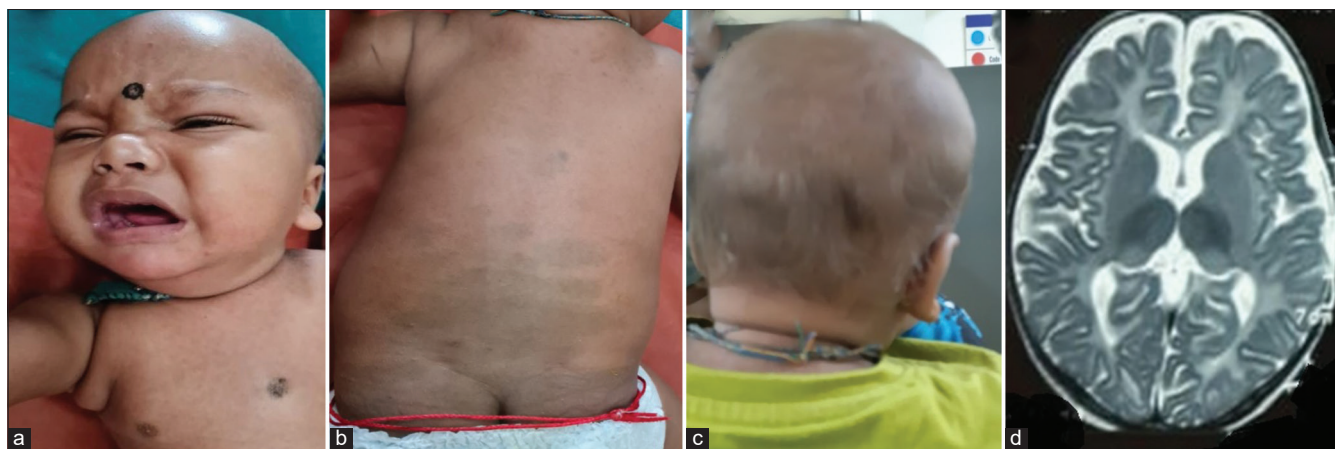

Figure 1: The dysmorphic features are coarse facial features (a), Mongolian spots (b), sparse hypopigmented hair (c), and an magnetic resonance imaging of the brain showing hypomyelination with T2-weighted bilateral hypointensity of the thalamus (d).

The neuroregression in the current scenario can be attributed to GM1 gangliosidosis; however, vitamin B12 may also add to the problem. Whether vitamin B12 deficiency is a single association or the effect of GM1 gangliosidosis warrants further studies. In the current case, the deficiency can be attributed to nutrition due to maternal deficiency. The current scenario may represent an association.

CONCLUSION

Here is a rare case of neuroregression presenting with both reversible ITS and irreversible causes of GM1 gangliosidosis in the same child, so one should consider simple treatable causes when diagnosed with neurodegenerative disorders to improve the outcome.

Declaration of patient consent

The authors certify that they have obtained all appropriate patient consent.

Financial support and sponsorship

Nil.

Conflicts of interest

There are no conflicts of interest.

REFERENCES

1. Nicoli ER, Annunziata I, D'Azzo A, Platt FM, Tiffit CJ, Stepien KM. GM1 gangliosidosis-a mini-review. *Front Genet* 2021;12:734878.

2. von Schenck U, Bender-Götze C, Koletzko B. Persistence of neurological damage induced by dietary Vitamin B-12 deficiency in infancy. *Arch Dis Child* 1997;77:137-9.
3. Caciotti A, Donati MA, Bardelli T, D'Azzo A, Massai G, Luciani L, *et al.* Primary and secondary elastin-binding protein defect leads to impaired elastogenesis in fibroblasts from GM1-gangliosidosis patients. *Am J Pathol* 2005;167:1689-98.
4. Gailus S, Suormala T, Malerczyk-Aktas AG. A novel mutation in LMBRD1 causes the cblF defect of Vitamin B(12) metabolism in a Turkish patient. *J Inherit Metab Dis* 2010;33:17-24.
5. Rutsch F, Gailus S, Suormala T, Fowler B. LMBRD1: The gene for the cblF defect of Vitamin B(12) metabolism. *J Inherit Metab Dis* 2011;34:121-6.
6. Coelho D, Kim JC, Miousse IR. Mutations in ABCD4 cause a new inborn error of Vitamin B12 metabolism. *Nat Genet* 2012;44:1152-5.
7. Takeichi T, Hsu CK, Yang HS. Progressive hyperpigmentation in a Taiwanese child due to an inborn error of Vitamin B12 metabolism (cblJ). *Br J Dermatol* 2015;172:1111-5.
8. Agrawal S, Nathani S. Neuro-regression in Vitamin B12 deficiency. *BMJ Case Rep* 2009;2009:bcr06.2008.0235.
9. Biegstraaten M, Mengel E, Marodi L. Peripheral neuropathy in adult Type 1 Gaucher disease: A 2-year prospective observational study. *Brain* 2010;133:2909-19.
10. Basgalupp SP, Siebert M, Ferreira C, Behringer S, Spiekerkoetter U, Hannibal L, *et al.* Assessment of cellular cobalamin metabolism in Gaucher disease. *BMC Med Genet* 2020;21:12.

How to cite this article: Gowda VK, Manohar V, Srinivasan VM, Narayana Vamyanmane D. Treatable and non-treatable neuroregression in the same child: A rare case of GM1 gangliosidosis with infantile tremor syndrome-ITS. *Karnataka Paediatr J* 2022;37:122-4.