



Review Article

Dental selfie: An innovative teledentistry tool for safe dental examination of children during the COVID-19 pandemic

Cheranjeevi Jayam¹, Thirunavukkarasu Arun Babu²

Departments of ¹Dentistry and ²Pediatrics, All India Institute of Medical Sciences (AIIMS), Mangalagiri, Andhra Pradesh, India.

***Corresponding author:**

Thirunavukkarasu Arun Babu,
Department of Pediatrics,
All India Institute of Medical
Sciences (AIIMS), Mangalagiri,
Andhra Pradesh, India.

babuarun@yahoo.com

Received : 06 December 2022

Accepted : 12 April 2023

Published : 31 May 2023

DOI

10.25259/KPJ_34_2022

Quick Response Code:



Oral and dental problems are one of the most common diseases of childhood which requires immediate intervention to prevent, treat or ameliorate the disease.^[1] When the COVID-19 pandemic broke out, dental clinics were the first ones to close due to the risk of oral spread of COVID-19. The shutting of dental clinics had prevented children from getting their routine dental care. Most of the non-emergency dental services have gradually resumed in most countries including India, thanks to the reduction in the number of COVID-19 cases and the introduction of COVID-19 vaccination.

Tele-consultation services were utilised to a great extent during the COVID-19 pandemic.^[2] Telemedicine played a significant role in keeping dental clinics functional during the COVID pandemic. We propose one innovation, 'dental selfies' which we used in our setup during the COVID pandemic and found to be very useful. All children contacting us for telemedicine consultations were encouraged to send a selfie picture of their oral cavity and teeth are taken depending on the clinical condition. Some of the common 'dental selfie' views that patients need to send based on our experience are individual maxilla [Figure 1a] view/mandibular view [Figure 1b], anterior view [Figure 1c], and zoomed image of the lesion in question.

In an era where smartphones with camera capabilities have become common in households, utilising the same to bridge the challenges during teleconsultation was largely rewarding. A few tips for taking good dental selfies include using adequate lighting and using the 'autofocus' feature to enhance the quality of the image. Telemedicine relies heavily on patients' information but with additional dental selfies, dentists can get more information on the dental condition. Dental selfies can be used for initial screening of the disease and contactless follow-up of conditions. These also reduced the chances of 'white coat syndrome' and anxieties associated with physical consultations, time-saving and more convenient for children and parents.^[3] However, this innovation is not without any disadvantages. Image resolution issues/diminished quality of image due to inherent filtering by media software can pose difficulties.^[4] There is a chance of misdiagnosis due to the reduced scope of clinical examination.^[5]

In spite of these disadvantages, this innovation has a potential role in teledentistry and also in supplementing the existing old-fashioned format of physical consultation and is worth exploring.

This is an open-access article distributed under the terms of the Creative Commons Attribution-Non Commercial-Share Alike 4.0 License, which allows others to remix, transform, and build upon the work non-commercially, as long as the author is credited and the new creations are licensed under the identical terms.

©2023 Published by Scientific Scholar on behalf of Karnataka Paediatric Journal

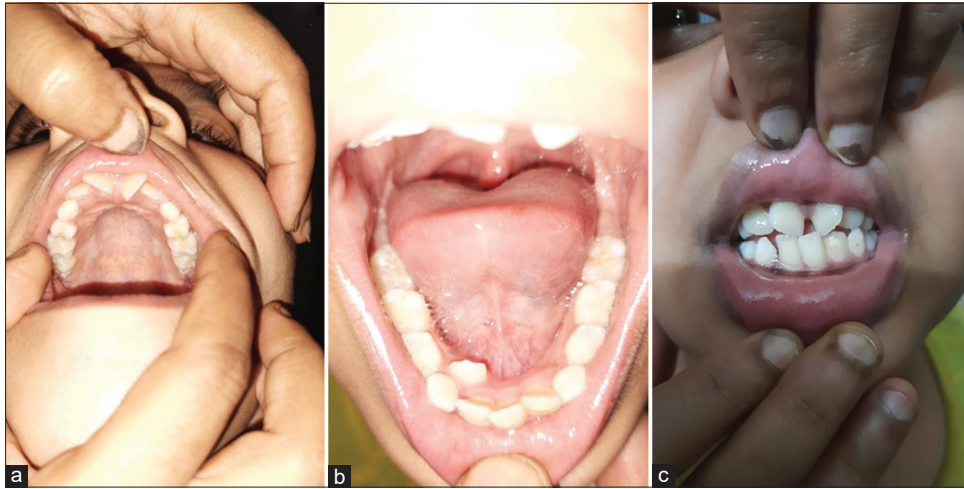


Figure 1: Common 'Dental Selfie' views showing (a) individual maxilla, (b) mandibular area and (c) anterior view.

Declaration of patient consent

The authors certify that they have obtained all appropriate patient consent.

Financial support and sponsorship

Nil.

Conflicts of interest

There are no conflicts of interest.

REFERENCES

1. Jayam C, Babu TA. Dental caries in children during COVID-19 pandemic-are we doing enough? *Indian Pediatr* 2021;58:999.

2. Sharmila V, Babu TA, Balakrishnan P. Optimizing telemedicine for providing obstetric and reproductive health care services during COVID-19 pandemic. *Int J Community Med Public Health* 2020;7:3278-83.
3. Luzzi V, Ierardo G, Bossù M, Polimeni A. Paediatric oral health during and after the COVID-19 pandemic. *Int J Paediatr Dent* 2021;31:20-6.
4. Georgakopoulou EA. Digitally aided telemedicine during the SARS-CoV-2 pandemic to screen oral medicine emergencies. *Oral Dis* 2020;27(Suppl 3):754-6.
5. Babu TA, Sharmila V. COVID-19 pandemic: Another nail in the coffin of the "dying art" of the physical examination. *Cancer Res Stat Treat* 2020;3:610.

How to cite this article: Jayam C, Arun Babu T. Dental selfie: An innovative teledentistry tool for safe dental examination of children during COVID-19 pandemic. *Karnataka Paediatr J* 2023;38:14-5.